

**The Central Processing of Pruritus in Atopic Dermatitis using Arterial Spin  
Labeling Functional MRI- Final Report NEASE**

**Principal Investigator: Gil Yosipovitch MD**

**Department of Dermatology**

**Phone (336) 716-2901**

**Fax (336) 716-7732**

**gyosipov@wfubmc.edu**

**Co-Investigators: Robert C Coghill PhD**

**Department of Neurobiology and Anatomy**

**The Central Processing of Pruritus in Atopic Dermatitis using Arterial Spin  
Labeling Functional MRI- Final Report NEASE**

Yozo Ishiiji<sup>1</sup>, Tejesh Patel<sup>1</sup>, Robert C. Coghill<sup>2</sup>, Robert A. Kraft<sup>3</sup>, Yoshitetsu Oshiro<sup>2</sup>,  
Gil Yosipovitch<sup>1,2</sup>,

1. Department of Dermatology, Wake Forest University School of Medicine,  
Winston Salem, North Carolina, USA
2. Department of Neurobiology & Anatomy & Neuroscience Program, Wake Forest  
University School of Medicine, Winston Salem, North Carolina, USA
3. Department of Biomedical Engineering, Wake Forest University School of  
Medicine, Winston Salem, North Carolina, USA

**INTRODUCTION**

Recent research has clearly shown a central processing of pruritus. However, all of the studies to date have been limited to healthy human subjects. In addition, these studies have used either blood oxygen level dependent functional MRI (BOLD fMRI) or positron emission tomography (PET) to assess brain activity. We have reason to believe that the emerging technique of fMRI using Arterial Spin Labeling (ASL) is more suited to assess pruritus related brain activity due to its ability to capture steady state long-term changes. In the current study, we compare the central processing of pruritus in healthy and atopic dermatitis subjects using the novel technique of ASL fMRI.

## **METHODS**

### *Subjects*

A total of 16 subjects participated in this study; 7 with atopic dermatitis (4 men, 3 women, mean age  $\pm$  SD:  $33.1 \pm 11.7$ ) and 8 healthy volunteer (4 men, 4 women, mean age  $\pm$  SD:  $34.6 \pm 10.0$ ). Atopic dermatitis was diagnosed by the criteria of Hanifin and Rajka. Healthy volunteers were matched for age and gender.

### *Induction of itch sensation*

Itch was evoked by histamine iontophoresis applied to the ventral forearms of atopic dermatitis and healthy subjects. Of note, histamine was applied to lesional skin in atopic dermatitis subjects. For iontophoresis, a 1% solution of histamine was dissolved in 2% methylcellulose gel (Sigma, St. Louis, USA) and was administered with a current of  $200\mu\text{A}$  for 30 seconds (Perimed PF3826 Perilont Power device, Sweden). Iontophoresis was terminated 30 seconds prior to start of image acquisition.

### *ASL MRI Sequence*

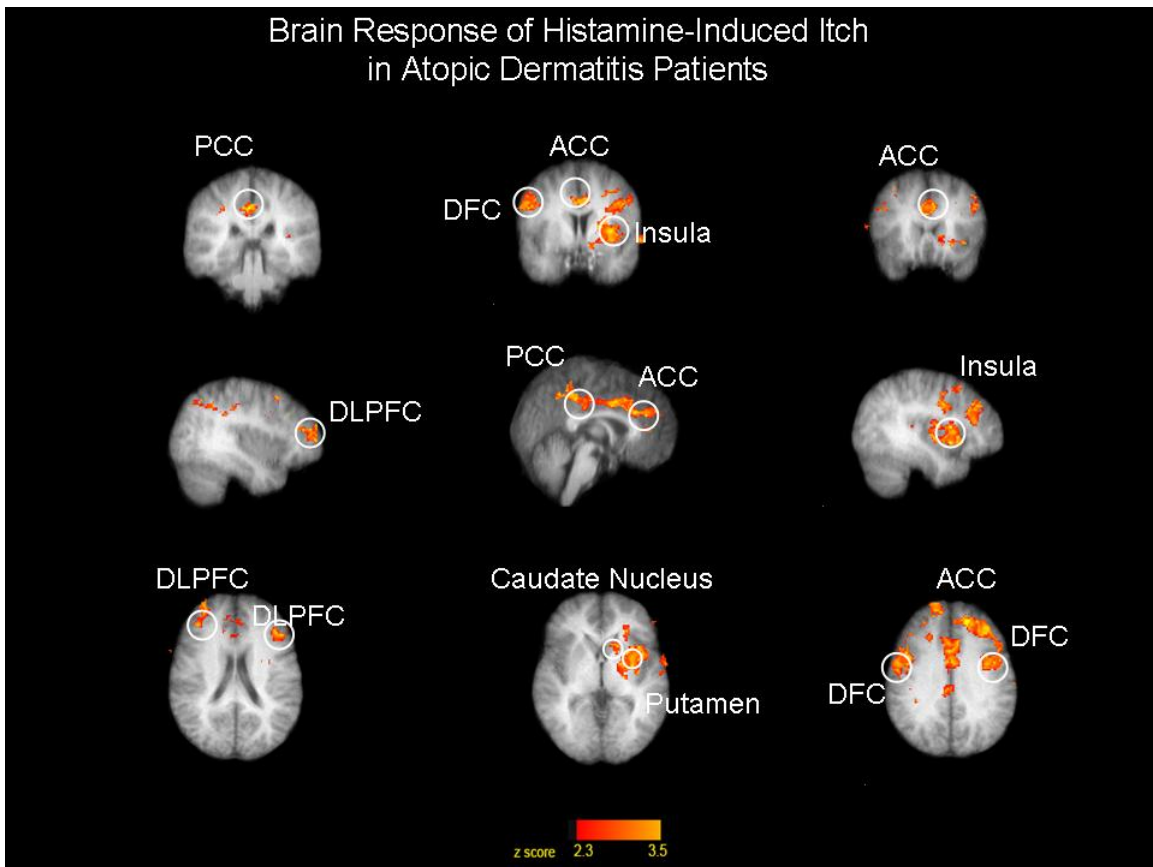
All images were acquired on a 1.5 Tesla GE scanner with a standard pulsed ASL technique - a Quantitative Imaging of Perfusion using a Single Subtraction with thin slice periodic saturation with a Flow-Sensitive Alternating Inversion Recovery (Q2TIPS-FAIR) sequence. In this technique, cerebral blood flow is used as an index of activity and is measured in a fully quantitative fashion.

## *Analysis*

The functional image analysis package FSL [Functional Magnetic Resonance Imaging of the Brain (FMRIB) Software Library (Center for FMRIB, University of Oxford, Oxford, UK)] was used for image processing and statistical analysis. Clusters of voxels exceeding a Z score  $>2.3$  and  $p < 0.05$  were considered statistically significant.

## RESULTS

*Figure 1. Pruritus-Induced Regional Cerebral Blood Flow (CBF) in Atopic Dermatitis Dermatitis.*

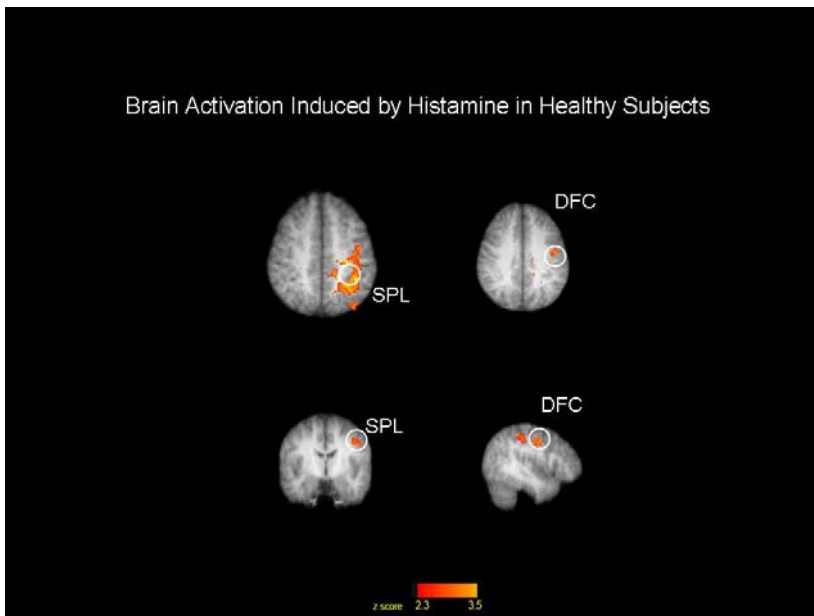


ACC: Anterior Cingulate Cortex, DFC:Dorsal Frontal Cortex, DLPFC:Dorsolateral Prefrontal Cortex, PCC: Posterior Cingulate Cortex

		z score		x		y		z		Function
		Right	Left	Right	Left	Right	Left	Right	Left	
DLPFC	Bilateral	3.51	2.62	32	-44	56	36	20	16	Attention and Memory
DFC	Bilateral	4.82	3.74	56	-50	6	-2	36	36	Motion
ACC	Bilateral	3.32	2.64	6	-4	42	30	6	26	Execution
PCC	Bilateral	2.97	2.32	2	-2	38	-26	22	32	Memory
Insula	Contralateral	4.70		-32		4		32		Emotions and Feelings
Putamen	Contralateral	2.92		-26		6		4		Reinforcement Learning
Caudate Nucleus	Contralateral	3.20		-14		16		2		Learning and Memory

**Figure 2. Pruritus-Induced Regional Cerebral Blood Flow (CBF) in Healthy Human**

**Subjects**



DFC:Dorsal Frontal Cortex, SPL:Superior Parietal Lobe

		z score (Left)	x (Left)	y (Left)	z (Left)	Function
DFC	Contralateral	3.13	-42	-10	40	Motion

SPL	Contralateral	2.7	-40	-24	46	Integrating Sensory Information
-----	---------------	-----	-----	-----	----	---------------------------------

## DISCUSSION

- We demonstrate significant differences in brain areas activated between healthy and atopic dermatitis subjects following histamine stimuli using ASL fMRI.
- We demonstrate robust activation of both sensory and non-sensory brain areas in atopic dermatitis subjects following histamine stimuli.
- The non-sensory areas include the dorsolateral prefrontal cortex as well as the anterior and posterior cingulate cortices. These areas are heavily involved with affective, cognitive and evaluative components of sensations such as pain<sup>5</sup>. The robust activation of these areas in pathological itch conditions may be important in modulating the affective and cognitive aspects of the itch experience.
- This study also shows ASL fMRI to be sufficiently sensitive to detect regional itch-induced changes in cerebral blood flow in chronic itch states and in healthy controls.

## Conclusion

- This preliminary study suggests that the neural networks activated by itch are different or amplified in atopic dermatitis subjects when compared to healthy controls. **ASL has the potential to be an important tool in identifying the neural networks that underlie chronic itch states.**

